

# Incisor Alignment With the Inman Aligner



by Stephen P. Warunek, D.D.S., M.S. and Brian D. Willison, C.D.T.

*Dr. Stephen Warunek is an orthodontist in private practice in Depew, NY. He is also clinical assistant professor and course director in the Department of Orthodontics at the State University of New York (SUNY) at Buffalo School of Dental Medicine where he maintains a faculty practice. He recently coordinated the Electronic Curriculum DVD Project for the SUNY at Buffalo Dental School's undergraduate orthodontic program. The project, customized for each dental program, provides students with the educational materials required to complete four years of dental school curriculum. Dr. Warunek is also a consultant to the Veterans Administration Medical Center and the State of New York Department of Health.*

*Brian Willison joined Great Lakes Orthodontics, Ltd., in Tonawanda, NY as a laboratory technician. After extensive training, he became an instructor and obtained National Board Certification in the field of orthodontics. Mr. Willison also is a faculty member and laboratory lecturer at SUNY @ Buffalo School of Dental Medicine's Department of Orthodontics. He has published a variety of articles in industry journals and lectures worldwide. He currently serves as senior instructor and research and development technical specialist at Great Lakes Orthodontics.*

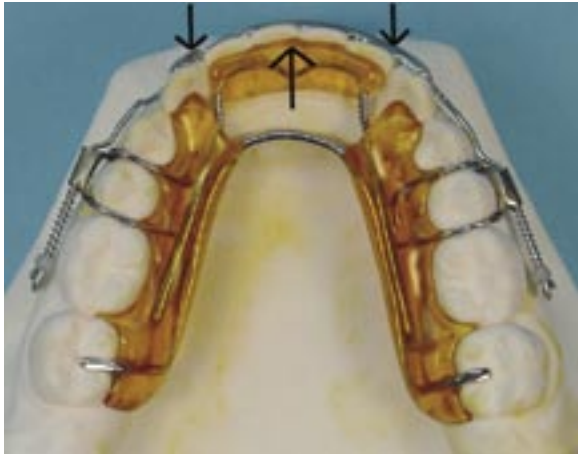
## ABSTRACT

A recently introduced orthodontic appliance uses nickel titanium (NiTi) springs in fixed and removable designs to correct several-millimeter discrepancies in incisor alignment. An extended range of tooth activation enables movement to occur with a single appliance, requiring minimal chair-side adjustments. This article presents the evaluation and analysis of appropriate cases, together with clinical management and treatment results with the removable version.

---

*Advantages of this device include the range of activation; lighter, more controlled forces; improved appliance retention; and patient comfort.*

---

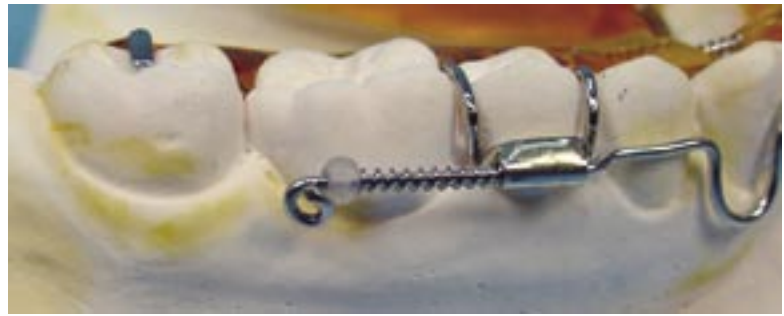

1a



1b

**Figure 1: Inman Aligner.**  
**1a: Mandibular appliance, occlusal view.**  
**1b: Activated lingual assembly.**  
**1c: Labial component.**



1c

## INTRODUCTION

In 1974, Barrer described the orthodontic alignment of incisors with a removable spring aligner appliance.<sup>1</sup> Also termed a *spring retainer*, this device is fabricated on a single model of teeth reset to ideal positions. A limited activation range, however, restricted applications to rather minor discrepancies.

The Inman Aligner™, a modification of the traditional spring retainer, was introduced in 2001 by Inman Orthodontic Laboratory (Coral Springs, FL).<sup>2</sup> Removable (Fig 1) and fixed designs use nickel titanium (NiTi) open-coil springs to apply light, near-constant forces on the lingual and labial surfaces of anterior teeth. Indications are anterior crowding or spacing up to approximately 3.0 mm (Fig 2), buccal

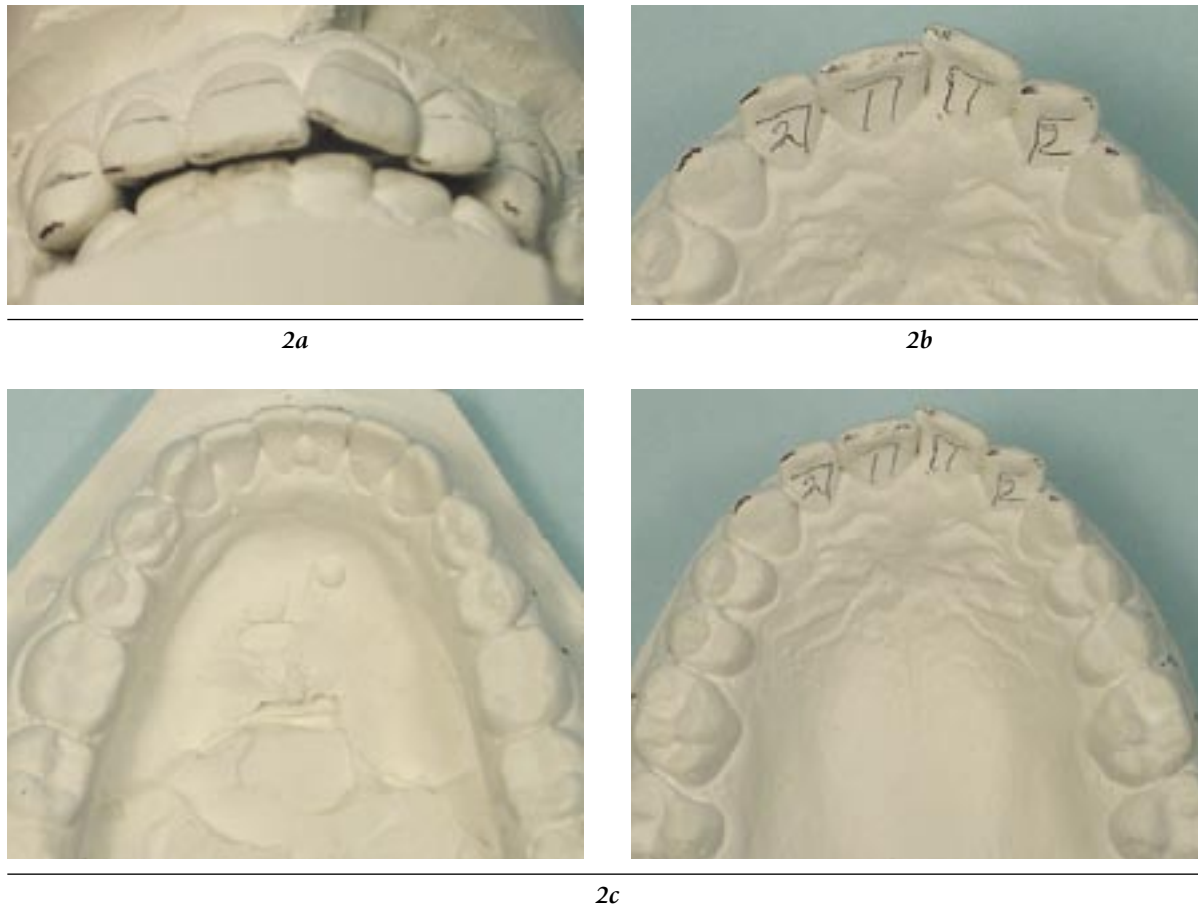
or lingual incisor tipping displacements on the order of 5 mm, and anterior cross-bite correction. These may be either preexisting or from orthodontic relapse. Advantages of this device include the range of activation; lighter, more controlled forces; improved appliance retention; and patient comfort. Also, chair-side adjustments are minimized and essentially limited to adjustments of clasps and springs.

## CLINICAL EVALUATION

Patient selection for this type of orthodontic treatment is the most important criteria for success. Following a clinical examination and obtaining diagnostic records, the severity of the malocclusion must be identified, and be within the scope of minor tooth movement. Many

individuals may require more comprehensive orthodontic treatment. The following factors should be considered:

- *Posterior occlusion.* A well-balanced skeletal relationship possessing an Angle Class I relationship is suggested. Also, there should be adequate buccal overlap with no cross-bite present in the posterior segment.
- *Anterior crowding/spacing*  $\leq 3\text{mm}$ . Tooth size and arch perimeter must be evaluated to determine the amount of crowding or spacing present in the anterior segment. Individuals with more than 3 mm of incisor crowding or spacing require more comprehensive procedures.



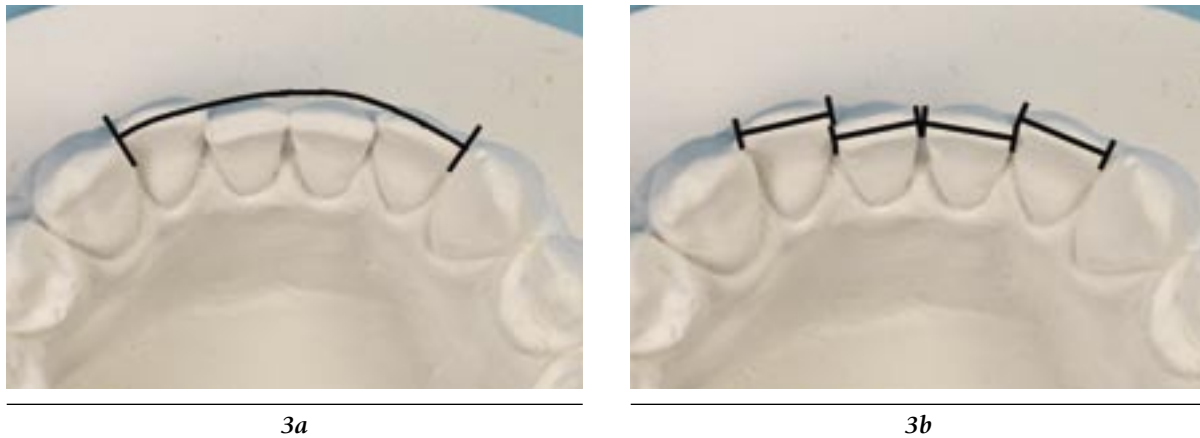
**Figure 2: Types of incisor irregularity appropriate for the Inman Aligner.**  
**2a:** Alignment of the four maxillary incisors is within a several-millimeter range. Interproximal reduction may be needed if space is not provided from incisor flaring.  
**2b:** To maintain an existing archform without labial flaring of the incisors, space must be gained by interproximal reduction.  
**2c:** Appropriate maxillary and mandibular incisor malalignment is present. Upper incisors are to be reset ideally to match the alignment of the lowers. Interproximal reduction will be needed to obtain proper alignment.

- **Intact, well-positioned roots.** Conventional brackets and archwires that are used during orthodontic treatment control the alignment of roots and crowns. Removable appliances for minor anterior alignment primarily affect crown tipping with limited movement of root apices. Therefore, well-positioned roots with normal size are necessary.

- **Crown anatomy.** Most of these appliances are ideal for use in the fully erupted permanent dentition. In some instances, a few designs may be considered in the late mixed dentition. For removable appliances, adequate undercuts should be available to secure the appliance to the dentition.
- **Patient cooperation.** Patients are required to wear these appli-

ances 24 hours a day, except during meals, brushing, and some sports; this will result in an efficient treatment time period. Patient responsibility for general maintenance (cleaning) is essential.

- **Patient habits.** Auxiliary cribs or pearls can be incorporated into most appliances to retrain tongue and thumb/finger habits. However, if the habit is not



**Figure 3: Evaluation of malaligned incisors.**

**3a: Arch perimeter along incisors, following ideal archform. Note that the maxillary incisor position should allow lower central incisors to move labially to ideal archform.**

**3b: Mesial-distal widths of incisors.**

controlled and the patient has no desire to quit, orthodontic correction is not likely. Patients with severe allergies or airway restrictions (e.g., those caused by mouth breathing; enlarged tonsils, adenoids, or turbinates) are contraindicated.

- **Temporomandibular joints.** An examination of joint function will identify internal noise, deviation during eccentric movements, and muscle pain that may contraindicate treatment.
- **Periodontal tissues.** Patients with tooth mobility or signs of periodontal disease are not appropriate candidates.

### MODEL ANALYSIS

Anterior crowding primarily involves the four incisors, but also may include the cuspids. The degree of crowding is determined by measuring the length of the ideal archform (arch perimeter) for those teeth re-

quiring alignment (Fig 3a), then comparing it to the sum of mesial-distal widths of each tooth involved in the malalignment (Fig 3b). The individual tooth values are added and compared to the ideal archform length (where the teeth need to be placed).

---

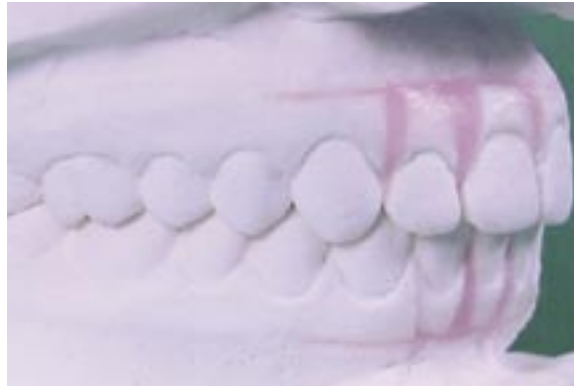***Patient selection for this type of orthodontic treatment is the most important criteria for success.***

---

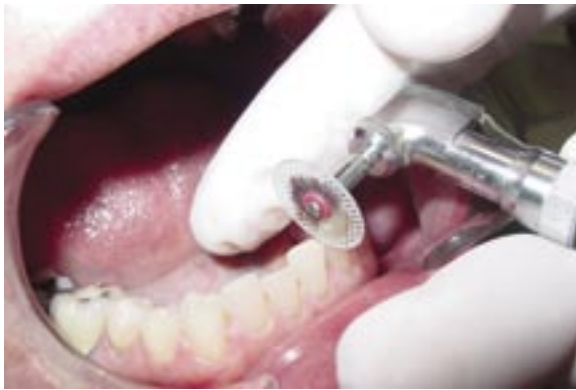These values are measured using a caliper (individual mesial-distal tooth size) and orthodontic silver solder (contour solder to ideal archform). If the sum of incisor widths is greater than the length of the ideal archform, the amount of incisor crowding is calculated. Should the sum of incisor widths be less than archform length, anterior spacing is present.

Anterior crowding usually is related to insufficient space along

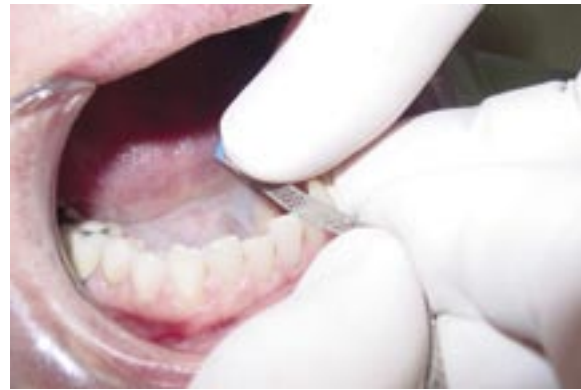the archform (arch perimeter) to accommodate teeth. To provide harmony between both, the arch perimeter must be enlarged and/or tooth sizes reduced. Enlargement of arch perimeter can be accomplished through arch expansion, either in a transverse or anterior-posterior direction. Although transverse or lateral expansion may appear to be an easy method of gaining additional space, one must consider the occlusal relationship of the opposing arch. In most cases related to minor anterior crowding, expansion in one arch usually necessitates some type of mirrored treatment in the opposing arch, thus making treatment more complex. Anterior arch expansion should be limited to less than 2 mm, especially with respect to relapse forces. Tooth-size reduction, also termed *stripping* or *interproximal reduction*, involves the removal of interproximal enamel that reduces mesial-distal widths.



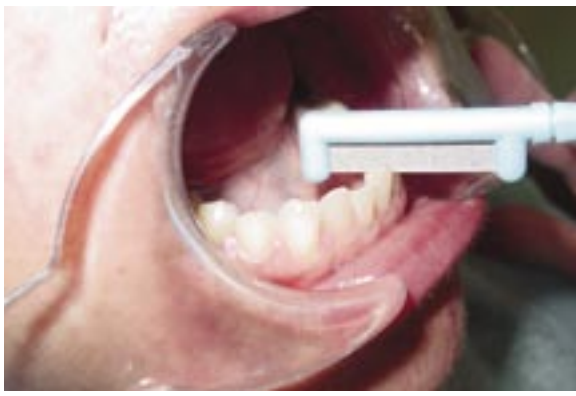*Figure 4: Models with partial set-up of incisors only.*



*5a*



*5b*



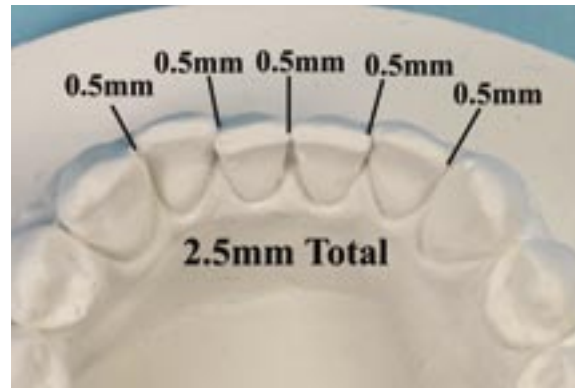
*5c*

*Figure 5: Interproximal reduction.*

*5a: Abrasive disc.*

*5b: Diamond strip.*

*5c: Interproximal reduction tool.*



*Figure 6: A maximum of 0.5 mm interproximal reduction per contact is recommended. Thus, a total of 2.5 mm of tooth-size reduction is possible from cuspid to cuspid.*

The clinician should indicate the teeth to be repositioned on a prescription form. In the laboratory, teeth to be moved are sectioned and reset to an ideal alignment (Fig 4).

### INTERPROXIMAL REDUCTION

In many cases, reproximation of interproximal contacts is necessary. Interproximal reduction<sup>3,4</sup> (also termed *enamel* or *interproximal reproximation, stripping, or enamel reduction*), is a procedure to create space for crowding and increase stability by flattening curved contact surfaces. This is accomplished with abrasive strips, discs, or burs (Fig 5). A space analysis of the anterior alignment (Fig 3) must be completed during the diagnostic phase of treatment and this may be complemented with a partial or gnathologic diagnostic setup. Crowding up to 2.5 mm may be resolved, without flaring the anterior teeth labially, by removal of enamel between the five contact areas (Fig 6). Many authors recognize reduction of one-half of the interproximal enamel per mesial or distal surface as a safe procedure.<sup>3,6</sup> This represents .5 mm per contact for 2.5

mm of total space to be gained between the cuspids. In terms of safety, hand-held or motor-driven abrasive strips are preferred for reproximation, but care still must be taken to avoid trauma to the interdental papilla. Surfaces prepared with coarse abrasive products should always be finished with finer grades.

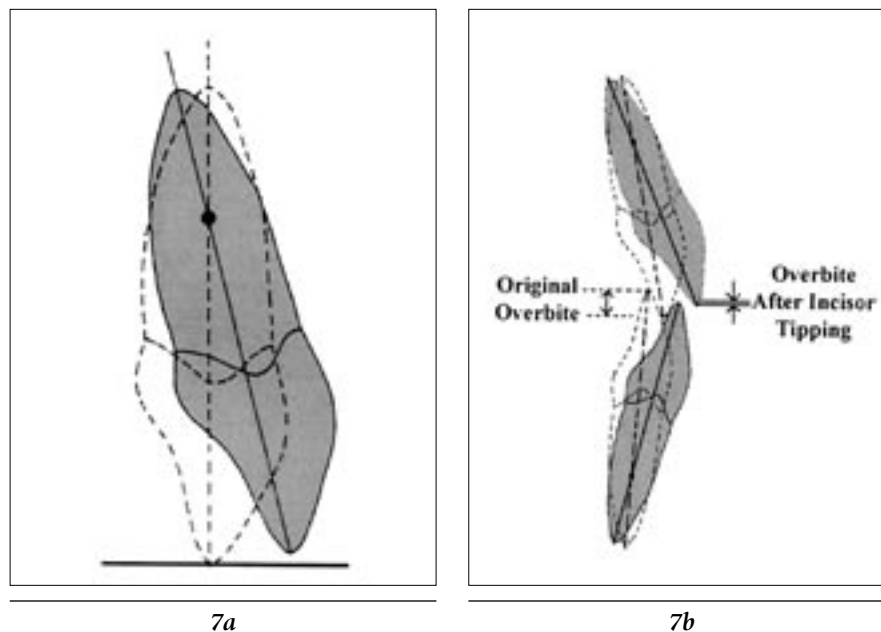
It is advantageous to complete reproximation during one appointment, as a thickness gauge can verify each interproximal space opened. For example, the flat end of a periodontal probe (Hu-Friedy; Chicago, IL) measures approximately .25 mm at the 1–3 mm portion and .5 mm at the 7–9 mm portion. Alternatively, a leaf gauge (Great Lakes Orthodontics, Ltd.; Tonawanda, NY) used in occlusal registration procedures has individual plastic strips that are .125 mm in thickness. The most precise determination of the amount of enamel removed is made by reducing one proximal surface at a time with a single-sided abrasive strip.

Reproximation over multiple appointments also can be an option. First, the thickness of the strip must be accurately measured with a mi-

croimeter. Interproximal enamel is removed until the strip passes with minimal binding. This represents the approximate strip thickness and space opened. For example, Brasse-ler (Savannah, GA) medium (blue) or fine (red) Vision Flex® diamond strips measure 0.1 mm in thickness. Reduction of five anterior contacts thus removes 0.5 mm of enamel per appointment (Fig 6).

Abrasive discs in a low-speed handpiece permit faster removal but present an increased risk of soft tissue injury. Also, these enamel surfaces must be further contoured and finished by hand with flexible strips. An in-office topical fluoride rinse is recommended following any enamel reduction procedure.

A distinction should be noted between the preceding procedures to resolve minor anterior crowding and another space-gaining method known as *air-rotor stripping*.<sup>5,8</sup> The latter technique removes up to 9 mm of enamel (6.4 mm from the posterior contacts) with a high-speed handpiece in combination with bands, brackets, and archwires in comprehensive orthodontic treatment.



*Figure 7: Decrease in incisal crown height as teeth are tipped labially.*

*7a: Maxillary incisor demonstrating shortening in crown height with tipping. The pivotal point of movement is in the apical one-third.*

*7b: As incisors are tipped labially, anterior overbite is reduced.*

## ANTERIOR ARCH EXPANSION

Another method to gain arch length is the labial movement of anterior teeth. In contrast to the bodily movement of teeth that can be effected with fixed brackets and bands, forces applied with the Inman appliance permit only tipping. A tipping force of moderate pressure sets up a center of rotation at approximately one-third the way up from the root apex. Tipping incisor crowns in a labial or lingual direction can create a pendulum movement of the incisal edge that will increase or decrease the crown height (Fig 7). In certain individuals, such as those with pre-existing protrusion, strong labial muscle forces, or a shallow overbite

relationship, labial movement of the anterior teeth is not desirable. Interproximal reduction should be the option of choice for patients with incisor crowding who have ideal long axis incisal inclination and less than a 2 mm overbite/overjet relationship. In general, labial flaring of the incisors should be limited to less than 2 mm.

---

*When both arches are being treated, the patient should wear the maxillary appliance to gain overjet space prior to treatment in the mandible*

---

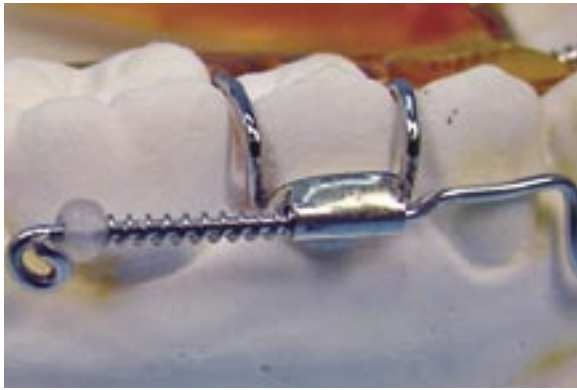## APPLIANCE ADJUSTMENTS

Common appliance adjustments include those to the labial and lingual components (Figs 8 & 9) and Adams Clasps (Fig 10).

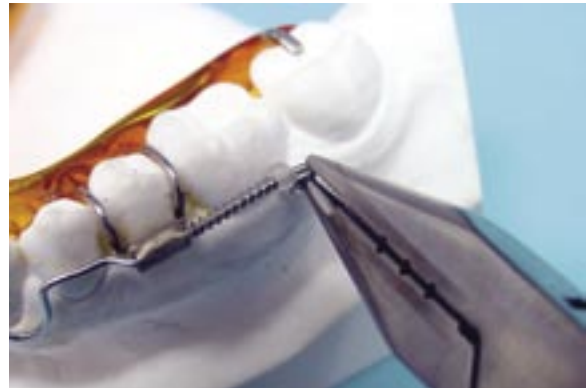### LABIAL SPRING COMPONENT

The labial component may be adjusted by removing coil springs to reduce the retracting force. Simply grasp one end of the coil with Jarabak pliers and pull to remove the desired length. Cut pulled coil flush with the labial component.

To increase the retracting force, grasp the helix distal to the pearl stop with Jarabak pliers and wrap wire in a labial direction around tip



8a




8b

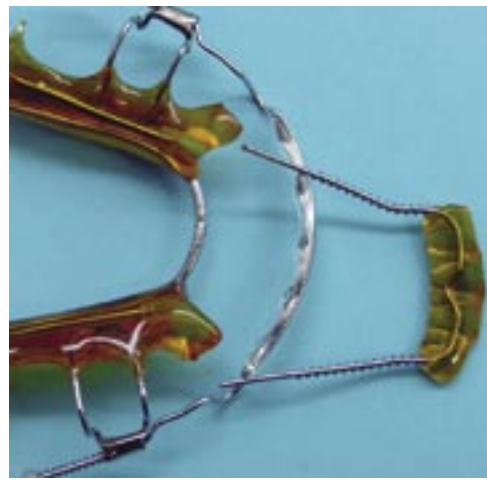*Figure 8: Labial adjustment area.*

*8a: Labial component.*

*8b: Bend wire to compress coil.*



9a

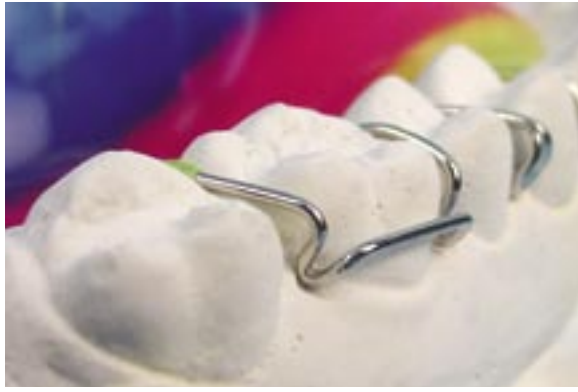

9b

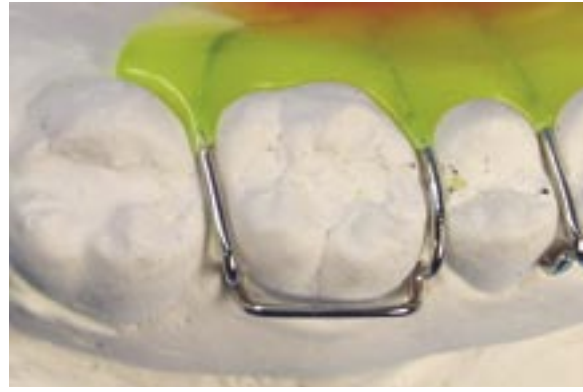*Figure 9: Lingual spring assembly.*

*9a: Lingual assembly engaged.*

*9b: Lingual assembly removed.*



10a

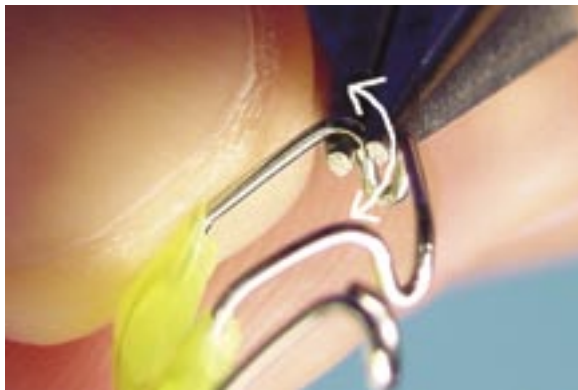

10b

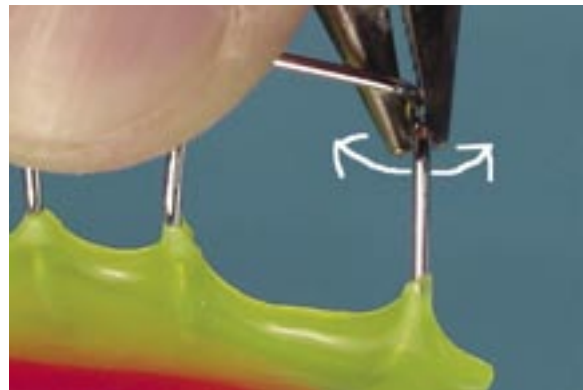
**Figure 10: The Adams Clasp.**

**10a: Facial view.**

**10b: Occlusal view.**



11a

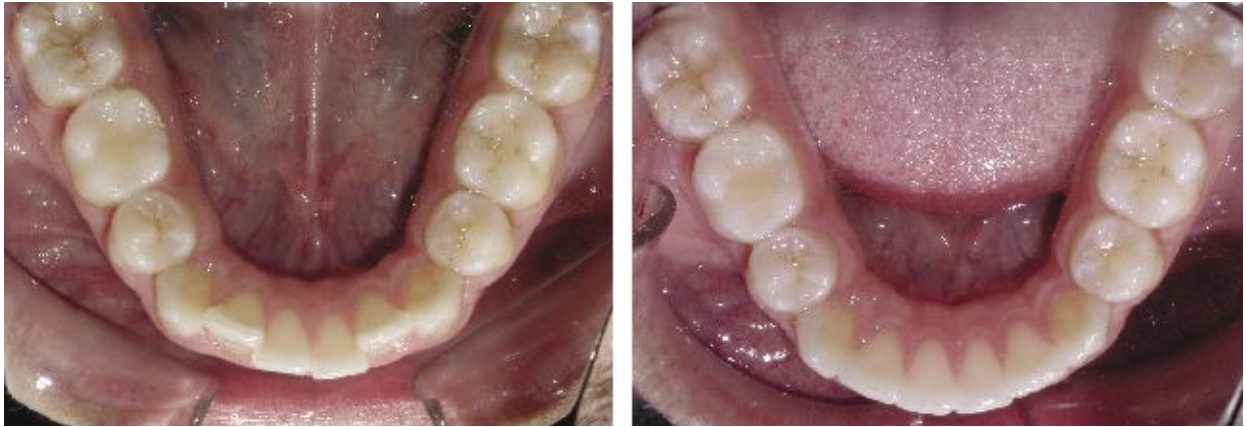

11b

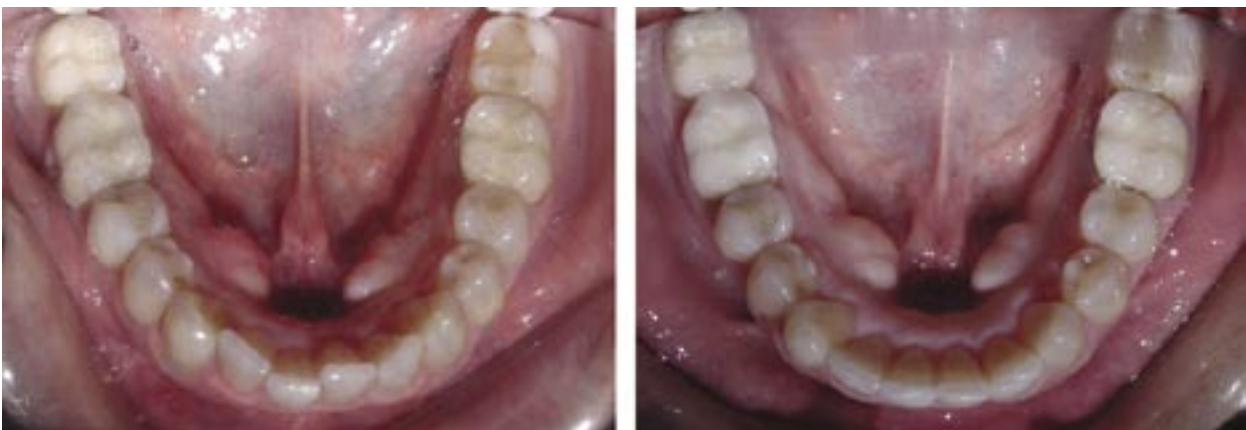**Figure 11: Adjustment of Adams Clasp.**

**11a: Hold wire at the occlusal embrasure area with Jarabak pliers. While supporting the occlusal part of the clasp, twist pliers to bend "U" loop toward or away from the cervical margin of the tooth.**

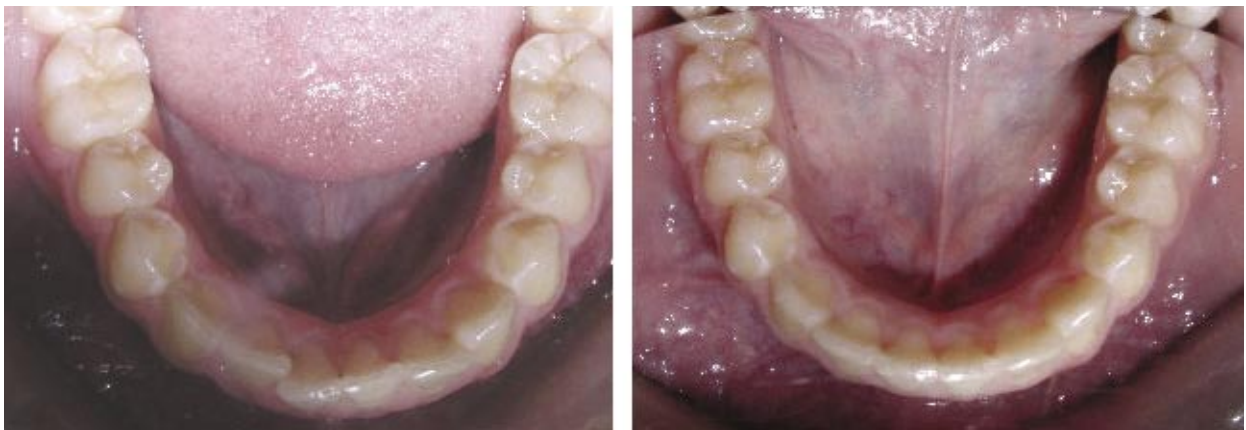**11b: Also, both arms of the "U" loop can be grasped with the same pliers and twisted toward or away from the tooth to adjust retention.**



12a



12b



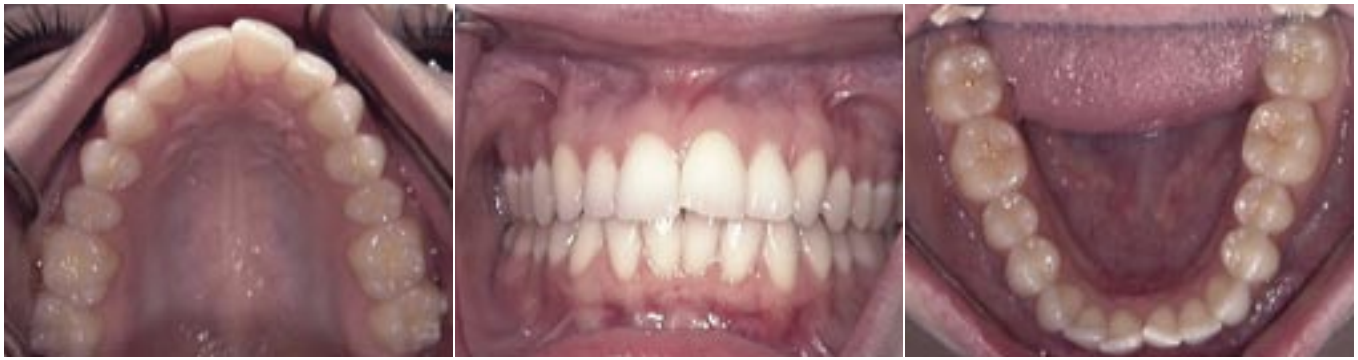12c

**Figure 12: Cases 1, 2, and 3; mandibular incisor alignment using the Inman Aligner.**

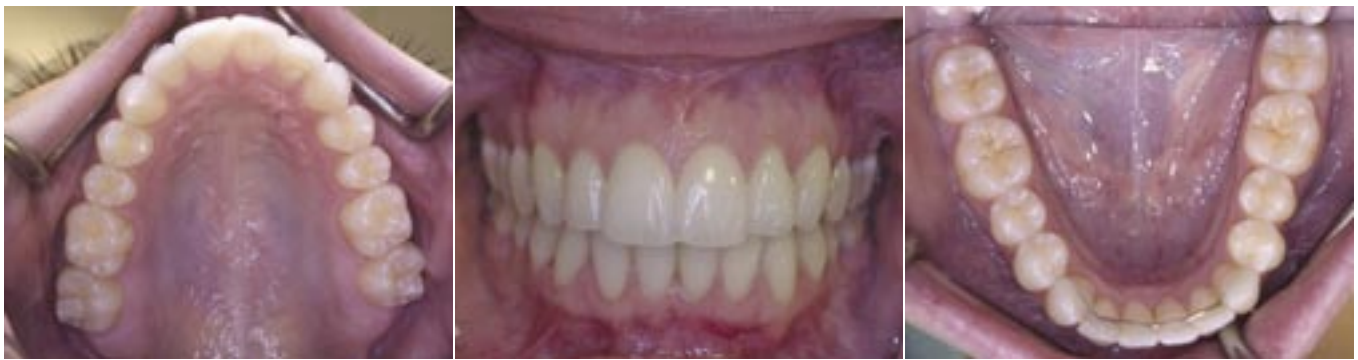**12a: Case 1, after six months of treatment.**

**12b: Case 2, after two months of treatment.**


**12c: Case 3, less than two months of treatment.**



13a




13b

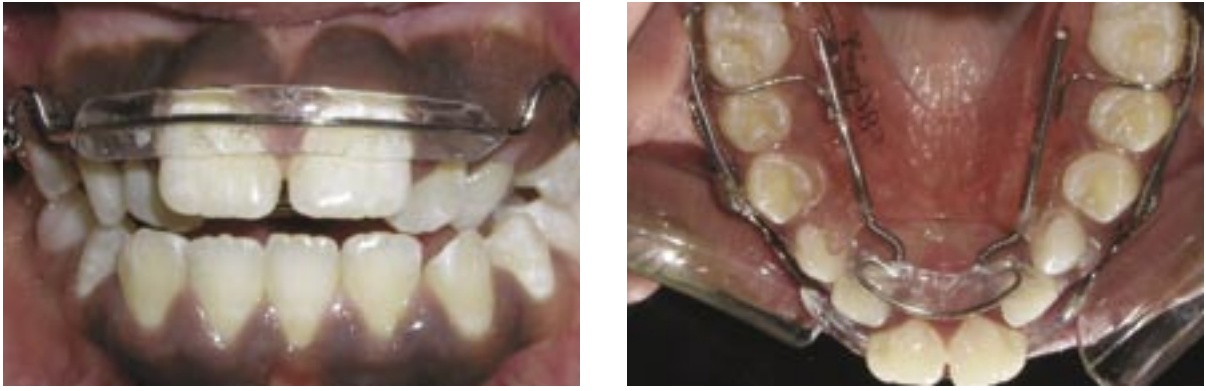

13c

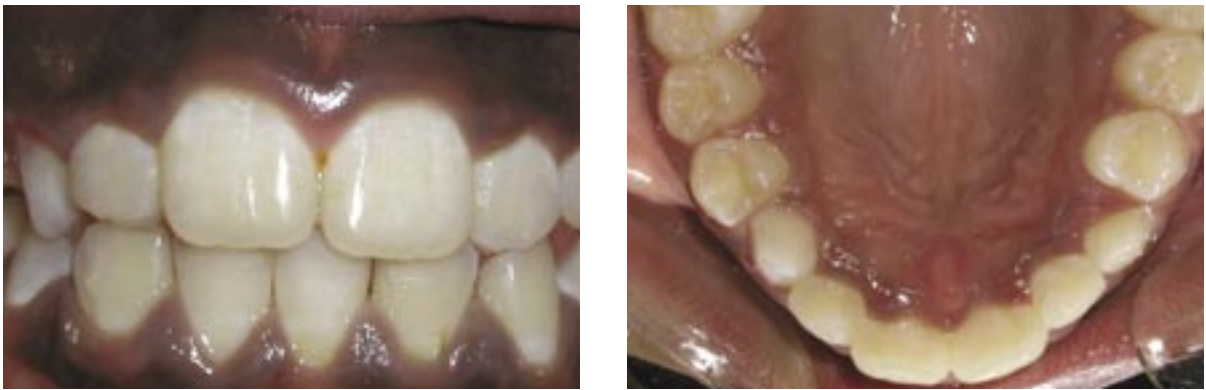**Figure 13: Case 4.**  
**13a: Pretreatment intraoral photographs.**  
**13b: 15-month progress intraoral photographs.**  
**13c: Pretreatment facial photographs.**  
**13d: 15-month progress facial photographs.**



13d



14a



14b

Figure 14: Case 5.

14a: Pretreatment intraoral photographs.

14b: 5-month progress intraoral photographs.

of the pliers. This will slide the pearl stop anteriorly, compressing the coil spring. Cut excess wire distal to the pearl, if necessary.

#### LINGUAL SPRING ASSEMBLY

To adjust the force applied by the lingual spring, gently pull this assembly toward the anterior. Pull evenly, making sure not to bend wire extensions that fit into tubes in the acrylic. Once the lingual assembly is disengaged, 0.010 in. x 0.030 in. of NiTi coil spring can be added or removed.

Unite the spring assembly into the tubes without distorting the wire

extensions. Slight compression of these extensions may be necessary to align with tubes in the acrylic. Lingual acrylic mesial to stainless steel tubes may need to be relieved, in some cases, to allow greater distal compression of the lingual assembly.

#### ADAMS CLASP

The Adams Clasp is most retentive on fully erupted teeth. This design provides the strongest anchorage to a single tooth compared with other clasps. A .028-inch wire Adams Clasp is available in a preformed design or can be made from

straight wire sections. Retention is supplied from the position of the two "U" loops against the facial-cervical corners of the tooth's crown. Adjustments can be in horizontal or vertical directions (Fig 11).

#### CASE REPORTS

When both arches are being treated, the patient should wear the maxillary appliance to gain overjet space prior to treatment in the mandible. Due to the extensive travel capability of the modular Inman Aligner parts, seating is very easy. In severe crowding cases, a button shape of composite may be placed on the most

lingual tooth (or teeth), incisal to the lingual spring component. This will prevent the spring from slipping toward the incisal. Insert the distal segment of the appliance while gently pulling the labial component. Lightly press the appliance in place to securely seat it on the dentition.

Patient cooperation is essential. A patient should wear the removable type of appliance full-time except during eating, brushing, and sports.

Clinical examples of incisor alignment shown in Figures 12–14 illustrate both positive results and some limitations. In Figure 13, slight rotation of the maxillary left lateral incisor is still present. Under conditions of optimal compliance, further adjustment of spring compression typically completes this movement. The authors' personal communication with laboratories licensed to manufacture these appliances (Inman Orthodontic Laboratories, Inc. and Great Lakes Orthodontics, Ltd.) indicates that some clinicians use this device to improve alignment and complete ideal esthetics with veneers or other cosmetic procedures.

As shown in Figure 14, the patient presents with a 3 mm anterior

dental open bite characterized by 5 mm labial tipping of the maxillary central incisors. The maxillary lateral incisors and left primary cuspid are in cross-bite. The maxillary midline is coincident with soft tissue features and the mandibular midline is displaced 2.5 mm to the right of the correct upper. 5-month progress photographs (Fig 14) show that the maxillary central incisors have tipped palatally, establishing a 2 mm overbite. The cross-bite also has been corrected and the midlines are not aligned. This result is consistent with the effects of incisor tipping expected with a removable appliance.

## SUMMARY

The Inman Aligner uses super-elastic open-coil springs to correct limited amounts of incisor tipping, rotations, and crowding with minimal chair-side adjustments. Cases have been presented to demonstrate representative results and limitations. It must be emphasized that all the patients whose cases are discussed in this article cooperated fully and wore their appliances extensively throughout the entire course of treatment. *AW*

## Acknowledgments

The authors thank the following individuals for providing photographs of clinical cases: Dr. Peter Wohlgermuth, Boca Raton, FL (Fig 12); Dr. John Marchetto, Weston, FL (Fig 13); and Dr. Paul Brosnan, Burke, VA (Fig 14).

## References

1. Barrer HG. Protecting the integrity of mandibular incisor positioning through keystone procedure and spring retainer appliance. *J Clin Ortho* 9:486-494, 1975.
2. Bowman SJ. The Inman Aligner. *J Clin Ortho* 37:438-442, 2003.
3. Proffit WR. *Contemporary Orthodontics* (3rd ed.). St. Louis, MO: Mosby; 2000.
4. Graber TM, Vanarsdall RL. *Orthodontics: Current Principles and Techniques* (3rd ed.). St. Louis, MO: Mosby; 2000.
5. Sheridan JJ. Air-rotor stripping. *J Clin Ortho* 19:43-59, 1985.
6. Radlanski RJ, Jager A, Zimmer B. Morphology of interdentially stripped enamel one year after treatment. *J Clin Ortho* 23:748-750, 1989.
7. Sheridan JJ. Air-rotor stripping update. *J Clin Ortho* 21:781-788, 1987.
8. Sheridan JJ, Ledoux PM. Air-rotor stripping and proximal sealants: An SEM evaluation. *J Clin Ortho* 23:790-794, 1989.

